

# Endoscopic endonasal surgery for parasellar tumors with malleable tools

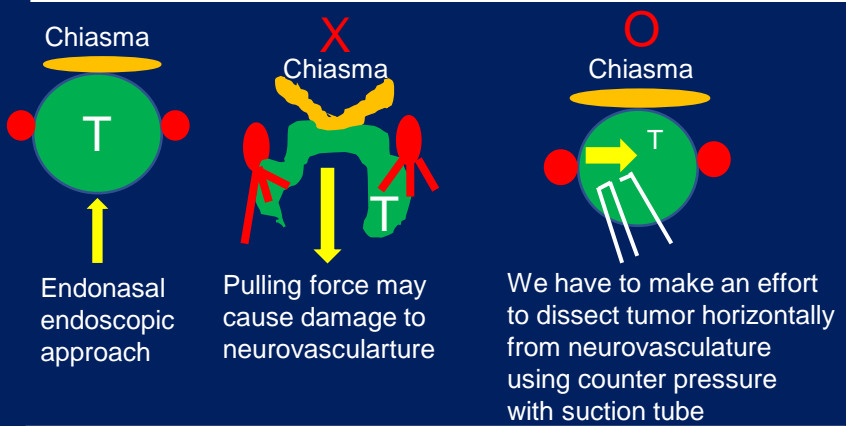
Department of Neurosurgery, Nara Medical University, Kashihara, Nara, Japan

Fumihiko Nishimura, Kenta Nakase, Shohei Yokoyama, Miho Kakutani, Ai Okamoto, Park Young-Soo, Shuichi Yamada, Ichiro Nakagawa, Kentaro Tamura, Ryosuke Matsuda, Yasuhiro Takeshima, Masashi Kotsugi, Hiroyuki Nakase

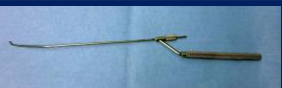## Objective

To present endoscopic endonasal surgery for parasellar tumors with malleable tools.

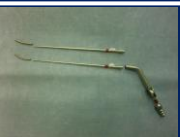## Tips for safe direction of dissection force during endonasal endoscopic surgery



## Malleable dissector



## Suction tube with attached flexible nozzle



## Flexible curette forceps



Curette forceps with 240mm long shaft and flexible tip. Curette rotates 360 degrees and bend both left and right.

## Cases

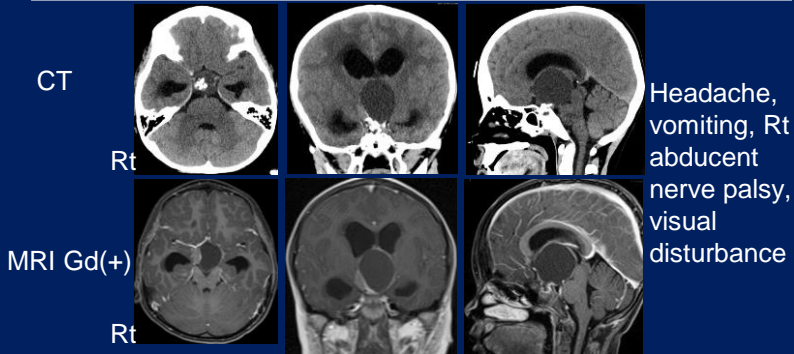
### Parasellar tumors 285 cases

PitNET	210
Rathke cleft cyst	35
Craniopharyngioma	10
Parasellar meningioma	12
Chordoma·Chondrosarcoma	5
Ohters	13
<b>Total</b>	<b>285</b>

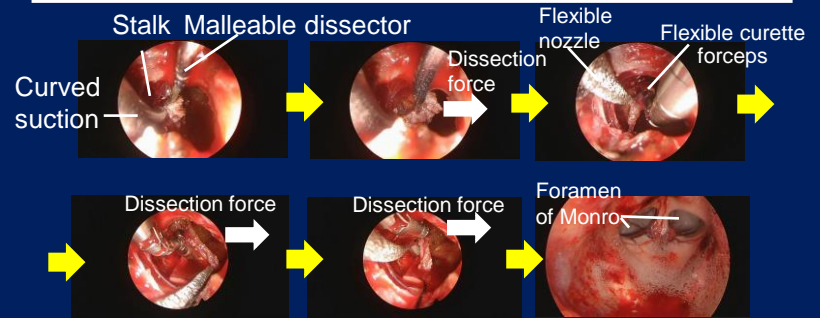
## Results

• Visual disturbance	224 before operation
Improved	190 (84.8%)
Not changed	28 (12.5%)
Worsened	6 (2.7%)
• Eye movement disturbance	18 before operation
Improved	15 (83.3%)
Not changed	3 (16.7%)
Worsened	0 (0%)

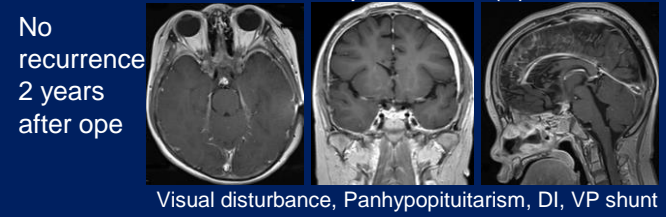
## Case 1.8y.o. Male Craniopharyngioma



## Case 1.8y.o. Craniopharyngioma



## Post-ope MRI Gd(+)



## Discussion

### Malleable tools

Need long malleable tools to reach tumors from narrow corridor in order to achieve adequate decompression.

### Next generation suction



## Conclusions

- Endoscopic endonasal surgery for parasellar tumors is safe and less invasive procedure.
- Although present malleable tools are useful, there is still issue to solve to get much more effective tools to reach the tumor site for removing big tumors in endoscopic endonasal surgery.